



International Conference on Medical Science, Medicine and Public Health

Hosted online from Jakarta, Indonesia

Website: econfseries.com

30th August, 2025

EVALUATION OF PATHOMORPHOLOGICAL CHANGES IN EXPERIMENTAL DIABETIC PURULENT-NECROTIC WOUNDS

Sabirov Djurabay Marifbaevich

DSc, Professor and chief of the Department of Anesthesiology and Reanimatology,
Center for the Development of Professional Qualifications of Medical Workers
(Tashkent, Uzbekistan)

Batirov Ulugbek Beshimovich

PhD, Assistant Professor of the Department of Anesthesiology and
Reanimatology, Center for the Development of Professional Qualifications of
Medical Workers (Tashkent, Uzbekistan)

Rosstalnaya Alla Leontevna

PhD, Assistant of the Department of Anesthesiology and Reanimatology, Center
for the Development of Professional Qualifications of Medical Workers
(Tashkent, Uzbekistan)

Sulaymanov Khurshid Orif ogli

Clinic ordinator of the Department of Anesthesiology and Reanimatology, Center
for the Development of Professional Qualifications of Medical Workers
(Tashkent, Uzbekistan)

Abstract

Currently, the treatment of diabetes mellitus and its complications remains an urgent problem. Patients with diabetic foot syndrome, a complication of diabetes mellitus, are increasingly losing their quality of life and ability to work. The treatment of diabetes mellitus and its complications affects the economic and financial efficiency of our country. Therefore, the new drug Reomannisol, produced in our country, helps to stop the purulent-necrotic process of the foot, which is a complication of diabetes mellitus.



Keywords: Experimental model of diabetic foot, purulent-necrotic process, experimental animals, alloxan, Reomannisol.

Introduction

Actually. Diabetes mellitus is a chronic disease caused by the absolute absence of insulin production by the pancreas, which leads to metabolic disorders in the body [6,7,8,17]. Due to the high mortality of patients, scientists around the world are currently developing and using various drugs [13,14,15]. For the use of newly created drugs in animals, the first question is to create their models [14,19,20,21]. One such model is the alloxan diabetes model. The study of pathomorphological aspects of chronic diabetic foot ulcers and purulent-necrotic changes in humans is difficult and not always controllable [8,13,14,15]. The healing of chronic wounds is subject to the general principles and pathophysiological aspects of reparative processes. This process depends on the stage of development of a chronic wound, the depth of the wound, the basic structure of the damaged organ, the general condition of the body, and the type of treatment [14,20,21,22]. Along with diabetes mellitus, the wound microflora plays a role in the reparative and regenerative processes of a purulent wound. What type of local treatment should be used for a chronic purulent ulcer that has developed against the background of diabetes mellitus remains a question [8,13,14,15,16].

After the development of the alloxan model of diabetes, the goal was to develop a new drug to correct violations of hepatoprotective and antioxidant processes in target organs [6,7,19,20]. Reomannisol is a complex drug with antihypoxic, antioxidant, antishock, rheological, detoxifying, diuretic properties. The main active ingredient is succinic acid and mannitol.

Target. Drawing up a technological algorithm for the treatment of purulent-necrotic lesions of the foot caused by diabetes mellitus at the stage after the complex treatment of experimental diabetic foot syndrome.

Materials and methods. Experiments From 2021 to 2022, experimental studies were carried out on 100 white sterile male rats weighing 180-200 g, kept in the vivarium of the Tashkent Medical Academy. All rats were observed every 12 hours day and night, they were given water to drink and kept at a constant temperature of 250-



International Conference on Medical Science, Medicine and Public Health

Hosted online from Jakarta, Indonesia

Website: econfseries.com

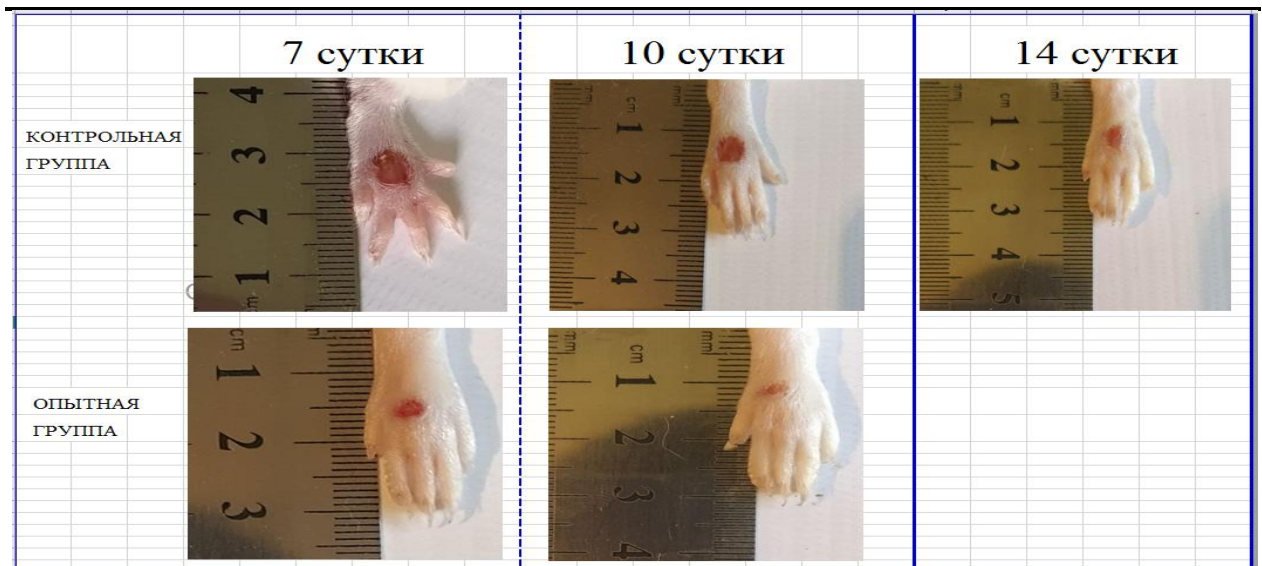
30th August, 2025

280°C. The experimental animals were divided into 4 groups: group 1 intact (unchanged group); 2nd control group - creation of an experimental model of a diabetic foot using traditional complex treatment against the background of alloxan diabetes; 3rd experimental group - according to the experimental model of diabetic foot - traditional treatment and rheosorbilactyl; group 4 - experimental group No. 2 - traditional treatment and rheomannisol [13].

On the skin of the pad of the right hind paw of each rat, full-thickness rectangular wounds 2 mm × 6 mm in size were inflicted with a scalpel. We used the traditional treatment of wounds every day (5% alcohol solution of iodine and Levomekol ointment), local traditional treatment for the experimental group, and the new drug Reomannisol was administered 1 time per day for 6 days at a dose of 1 ml per 100 g of body weight was treated by injection into the cavity [13,15,16,17].

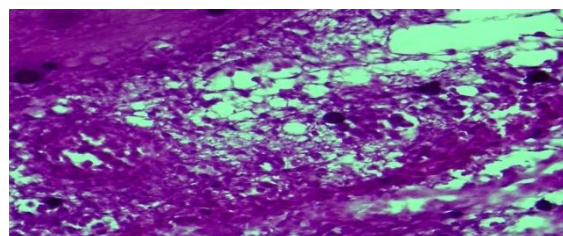
Rats were decapitated on days 1, 3, 5, 7, 10 and 14. The effectiveness of the drug was evaluated based on wound healing and an objective examination of the animal [14]. Criteria for evaluating the effectiveness of the drug on the wound: the duration and stage of inflammation around the wound site (edema, hyperemia, exudate), healing of the wound edges, development of granulation tissue, reduction of the surface of the wound defect. The L.N. test was used to determine the area of the wound. Popova (1942). A sterile cellophane plate is placed on the wound and the contour of the wound is applied to it. The drawing is transferred to graph paper and the area of the wound is calculated.

Results. In the experimental group, the scab was difficult to detach, tissues in places with a slight overlay of fibrin. Swelling in the area of the foot wound continued in the rats of the control group on the 7-8th day, but in the rats of the experimental group it decreased already on the 5th day after the injury. on the 7th day after the wound in rats from the experimental group when using the drug, a significant decrease in the area of wounds ($4.3 \pm 0.05 \text{ mm}^2$; $p < 0.001$) was noted, 2 times than its original wound, and 1.5 times than in rats control group ($6.5 \pm 0.07 \text{ mm}^2$), due to wound contraction and marginal epithelization (Picture 1).

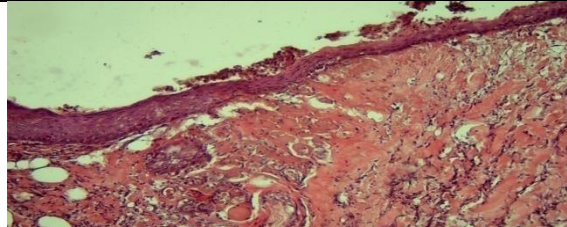


Picture 1 - Images of foot wounds on days 7, 10, 14 after injury and comparison of the size (area) of wounds between control and experimental groups.

The crust from the wound was removed with great difficulty, under it there was a brightly granulating wound defect with pronounced signs of marginal epithelization, far ahead of the control group. Also, in the rats of the experimental group, almost complete closure of the wound defect is observed, it is noted that the wound bleeds well, this indicates an improvement in blood circulation in the wound, which exceeds this indicator over the control group. When examining the histological section of the wound under a microscope, there is a restriction and rejection of the destructive-necrotic tissue on the surface of the wound (Picture 3).



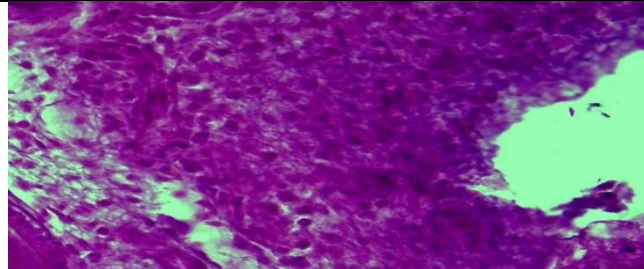
Picture 2. Experimental group, 7 days. Rejection of necrotic tissue on the surface of a diabetic wound. Staining: hematoxylin-eosin. Magnification: 10x40.



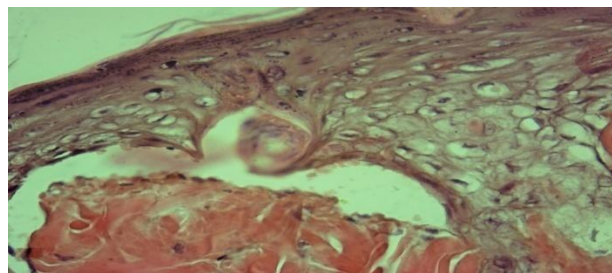
Picture. 3. Control group, 7 days. diabetic wound. Preservation of necrotic mass and inflammatory infiltrate in the bottom of the diabetic foot. Staining: hematoxylin-eosin. Magnification: 10x40.

At the same time, in the circumference of the wound, the tissue of the epidermis is compacted and the focus of destruction of the dermis is delimited from the underlying healthy elements of the tissue of the dermis. As part of the destructive tissue, the development of the process of disintegration and disorganization of both cellular and fibrous structures is determined. In the underlying connective tissue of the dermis, a neoplasm of hair follicles, compaction of fibrous structures and an increase in the proliferative activity of histiocytic cells are determined.

On the 7th day after treatment with the traditional method of an experimental model of a diabetic foot in the control group, at the bottom and circumference of the diabetic wound, necrobiotic tissue and acute inflammatory infiltrate are preserved in the form of a structureless tissue mass, in the circumference of which it is infiltrated with leukocyte cells, and a picture of the formation of poorly differentiated (granulation) is also found. tissue, the process of vasculogenesis is very weak (Picture 2). As part of the structureless mass, there are foci of edema and tissue vacuolization, as well as hematoxylin conglomerates and calcification. Thus, the development of microangiopathy phenomena took place, which makes it possible to consider diabetic microangiopathy as one of the morphofunctional manifestations of diabetes mellitus. By the 10th day in the experimental group, who received traditional treatment and Reomannisol, an independent almost complete closure of the wound defect and hair growth around the wound were noted (Picture 1), vacuolization and increased proliferative activity of cells in the basal layers (Picture 5).



Picture. 4. Control group, 10 days. diabetic wound. Formation of a dense inflammatory infiltrate around the wound of a diabetic foot. Staining: hematoxylin-eosin. Magnification: 10x40.



Rice. 5. Experimental group, 10 days. Compaction of the surface layers of the epidermis, fibrosis of the connective tissue of the dermis. Staining: hematoxylin-eosin. Magnification: 10x40.

The connective tissue of the dermis is compacted, without signs of an acute inflammatory process, the fibrous structures are transformed into dense, homogeneous, fibrous masses due to disorganization and fusion with each other. In them, cellular structures are localized along the periphery and around the vessels, and they are in a proliferative active state. On the 10th day after the treatment of diabetic foot with Reomannisol, regeneration of the integumentary stratified epithelium is noted in the form of sliding of epithelial cells onto the surface of the wound. At the same time, the epidermis is represented in the regeneration zone by several layers of active and hyperchromic epithelial cells. Under the epidermis, the formation of a basement membrane from loose fibrous structures is determined. In the tissue of the dermis, the presence of foci of reparative regeneration is determined in the form of excessive formation of fibrous, cellular structures that differ from the surrounding tissue by the presence of many vessels and proliferatively active



International Conference on Medical Science, Medicine and Public Health

Hosted online from Jakarta, Indonesia

Website: econfseries.com

30th August, 2025

histiocytic cells. Both the epidermis and the dermis show no signs of an acute inflammatory process. In the control group, on the 10th day, a wound defect of about 4.9 ± 0.05 mm² remains (Picture 1). At the bottom and in the circumference of the wound, the formation of inflammatory granulation tissue with foci of necrosis and hemorrhage is noted. The inflammatory infiltrate is represented by proliferative active lymphoid and histiocytic cells (Picture 4), randomly arranged fibrous structures consisting of argyrophilic and collagen fibers. In the center of the inflammatory infiltrate, a defect surrounded by fibrinoid necrosis and a homogeneous fibrous mass is determined. In the circumference of the inflammatory infiltrate, the connective tissue is subjected to edema, loosening with the breakdown of fibrous structures, and cell necrobiosis. The wound healed on the 14th day of the experiment (Picture 1). Thus, hyperglycemia causes microvascular complications due to impaired angiogenesis, which leads to a prolongation of the inflammatory effect of the wound and the period of wound healing. The use of standard wound treatments (iodine and levomekol) and the drug rheomanisol, indicators of planimetric control over the course of the wound process in animals of this group (experimental) are at a consistently high level.

Finding. The rate of healing of wound defects in rats with diabetic foot syndrome in the control group falls on the 14th day, since the periods of resorption and rejection of necrotic tissues in the wound, damage to the vessels of the microvasculature (microangiopathy) are prolonged, and edema is observed for a long time. The wound process against the background of DM is characterized by late formation of angiogenesis, slowing down and impaired maturation of granulation tissue, marginal epithelialization. In the experimental group, in rats, along with the local traditional method of wound treatment, the drug Reomannisol was used intraperitoneally, as a result, wound healing was recorded on the 10th day from the moment the wound was applied to the foot of the rats. The use of local treatment and Reomannisol can enhance angiogenesis in the early stages of the experiment and restore disturbed microcirculation (neoplasms of blood vessels), increase macrophage response, fibroblast proliferation, maturation and remodeling of granulation tissue and its epithelization, reduce the inflammatory response, which leads to more effective and early healing wound area.



List of references

1. Yusufjanovich, E. U., Rafiqovich, Z. A., & Irsalievich, E. K. (2023). Assessment of the Process of Epithelialization After Complex Treatment of Diabetic Foot Syndrome. *Texas Journal of Medical Science*, 16, 19-23.
2. Ergashev, U. Y. (2022). Ernazarov Kh. I., Zohirov AR, Alzabni ID 2022. Complex Treatment of Experimental Model of Diabetic Foot Syndrome. *American Journal of Medicine and Medical Sciences*, 12(5), 471-480.
3. Ergashev, U. Y., Mustafakulov, G. I., Mominov, A. T., Yakubov, D. R., Zohirov, A. R., & Ernazarov, X. I. (2022). Effective of Simultaneous Surgeries in Chronic Immune Thrombocytopenia. *Jundishapur Journal of Microbiology*, 15(2), 638-644.
4. Yusufjanovich, E. U., & Rafiqovich, Z. A. (2023). Evaluation of the lipid peroxidase index in diabetic complications. *Conferencea*, 68-73.
5. Yusufjanovich, E. U., & Rafiqovich, Z. A. (2023). Treatment of purulent-necrotic lesions of the lower extremities with modern drugs. *Conferencea*, 88-94.
6. Ergashev, U. Y., Zohirov, A. R., Minavarkhojayev, R. R., & Mominov, A. T. (2023). IMPROVING METHODS FOR DIAGNOSING AND MONITORING ENDOTOXICOSIS IN EXPERIMENTAL DIAETIC FOOT SYNDROME. *World Bulletin of Public Health*, 19, 84-95.
7. Эргашев, У. Ю., & Зохилов, А. Р. (2023). ИЗУЧЕНИЕ ПАТОМОРФОЛОГИИ ПЕЧЕНИ ПРИ ЭКСПЕРИМЕНТАЛЬНОМ СИНДРОМЕ ДИАБЕТИЧЕСКОЙ СТОПЫ. *European Journal of Interdisciplinary Research and Development*, 12, 27-31.
8. Эргашев, У. Ю., Зохилов, А. Р., Мустафакулов, Г. И., & Моминов, А. Т. (2023). ОЦЕНКА ПРИМЕНЕНИЯ И ЭФФЕКТИВНОСТИ СОВРЕМЕННЫХ ОПЕРАТИВНЫХ ВМЕШАТЕЛЬСТВ НА ПАТОЛОГИЧЕСКИХ ПРОСТРАНСТВАХ ПЕЧЕНИ. *European Journal of Interdisciplinary Research and Development*, 12, 17-26.
9. Эргашев, У. Ю., & Зохилов, А. Р. (2023). ОЦЕНКА ЭФФЕКТИВНОСТИ МАЛОИНВАЗИВНЫХ ОПЕРАЦИЙ ПРИ МЕХАНИЧЕСКОЙ ЖЕЛТУХЕ И ПРИМЕНЕНИЕ АЛГОРИТМА. *European Journal of Interdisciplinary Research and Development*, 12, 6-16.



International Conference on Medical Science, Medicine and Public Health

Hosted online from Jakarta, Indonesia

Website: econfseries.com

30th August, 2025

10. Yusufjanovich, E. U., & Rafiqovich, Z. A. (2023). The Use of Endovascular Laser Coagulation in the Recurrence of Varicose Veins of the Lower Extremities. *International Journal of Scientific Trends*, 2(2), 24-31.
11. Yusufjanovich, E. U., Rafiqovich, Z. A., Tashkarganovich, M. A., & Tohirovich, G. B. (2023). ASSESMENT THE EFFECTIVENESS OF MINIMALLY INVASIVE SURGICAL METHODS IN ACUTE CHOLECYSTITIS. *International Journal of Scientific Trends*, 2(2), 14-23.
12. Yusufjanovich, E. U., Irisbaevich, M. G., Rafiqovich, Z. A., & Irsaliyevich, E. K. (2023). EVALUATION OF EFFECTIVENESS OF SPLENECTOMY IN CHRONIC LEUKEMIAS. *World Bulletin of Public Health*, 19, 79-83.
13. Rafiqovich, Z. A. (2023). CONTROL OF INDICATORS OF ENDOTOXICOSIS IN DIABETIC FOOT SYNDROME. *Conferencea*, 83-90.
14. Rafiqovich, Z. A. (2023). STUDY OF THE EFFECT OF LIPID PEROXIDASE ANALYSIS ON THE BODY IN DIABETIC FOOT SYNDROME. *Conferencea*, 76-82.
15. Rafiqovich, Z. A. (2023). MONITORING OF THE REGENERATION PROCESS IN PURULENT-NECROTIC PROCESSES OF THE LOWER EXTREMITIES. *Conferencea*, 189-194.
16. Rafiqovich, Z. A. (2023). OBSERVATION OF BIOCHEMICAL RESULTS IN EXPERIMENTAL DIABETIC FOOT SYNDROME. *Conferencea*, 181-188.
17. Зохиоров, А. Р. (2023). ОБОСНОВАНИЕ ПРОЦЕССОВ ЭПИТЕЛИЗАЦИИ И РЕГЕНЕРАЦИИ ПРИ ГНОЙНО-НЕКРОТИЧЕСКИХ ПРОЦЕССАХ НИЖНИХ КОНЕЧНОСТЕЙ ПРИ САХАРНОМ ДИАБЕТЕ. *Conferencea*, 174-180.
18. Ergashev, U. Y., Zokhirov, A. R., & Minavarkhujaev, R. R. (2022). Determination of changes in the lipid peroxidase index in purulent-necrotic lesions of the lower extremities.
19. Эрназаров, Х. И., Эргашев, У. Ю., Зохиоров, А. Р., & Каримов, Х. Я. (2022). ЭФФЕКТИВНОСТЬ ИСПОЛЬЗОВАНИЕ ПРЕПАРАТА РЕОМАННИСОЛ В ЛЕЧЕНИИ ЭКСПЕРИМЕНТАЛЬНОЙ МОДЕЛИ ДИАБЕТИЧЕСКОЙ СТОПЫ.



International Conference on Medical Science, Medicine and Public Health

Hosted online from Jakarta, Indonesia

Website: econfseries.com

30th August, 2025

20. Ergashev, U. Y., Zokhirov, A. R., & Minavarkhujaev, R. R. (2023). The study of pathological physiology of indicators of endogenous intoxication in purulent-necrotic lesions of the lower extremities.

21. Зохилов, А. Р., & Набиева, А. Ш. (2023). ИЗУЧЕНИЕ ПАТОМОРФОЛОГИЧЕСКИХ ОСОБЕННОСТЕЙ СОВРЕМЕННОГО ЛЕЧЕНИЯ ГНОЙНО-НЕКРОТИЧЕСКИХ ПРОЦЕССОВ ПРИ САХАРНОМ ДИАБЕТЕ. Interpretation and researches, 1(2), 25-36.

22. Ergashev U. Y. et al. THE STUDY OF DIAGNOSTICS AND PREVENTION OF PATHOPHYSIOLOGICAL PARAMETERS AFTER MODERN TREATMENT OF PURULENT-NECROTIC PROCESSES IN DIABETIC. – 2022.